

Tissue Processing Factors Influencing Descemet Stripping Automated Endothelial Keratoplasty Thickness and Endothelial Outcomes

Maria A. Woodward, N.D., M.S.¹, Nita G. Valikodath, M.S.¹, Bernardino Iliakis, MHA, CEFT²

ABSTRACT

Introduction: Descemet stripping automated endothelial keratoplasty tissue thickness can be modified by various tissue processing factors including microkeratome (MK) head size, anterior chamber pressure (ACP), and cut pass duration.

Objective: Our primary objective was to evaluate how changes in MK head size, ACP, and cut pass duration affect endothelial cell counts and tissue thickness.

Methods: Donor corneas underwent tissue processing under various combinations of MK head size, ACP, and cut pass duration. Endothelial cell density (ECD) and optical coherence tomography (OCT) were recorded both pre- and post-processing. We performed multivariable linear regression to determine if MK head size, ACP, and cut pass duration were associated with change in ECD or tissue cut depth as measured by OCT.

Results: 38 corneas underwent processing. For every 50 μm increase in MK head size, $77.32 \pm 6.71 \mu\text{m}$ more anterior tissue was cut ($p < 0.0001$). For every 5 mmHg increase in ACP, $15.19 \pm 6.59 \mu\text{m}$ more anterior tissue was cut ($p=0.03$). Cut pass duration was not associated with tissue cut depth ($p=0.19$). MK head size, ACP, and cut pass duration were not associated with changes in ECD (all $p > 0.05$).

Conclusions: Tissue processing parameters did not impact ECD. MK head size and ACP did affect tissue cut depth and is likely clinically significant.

Key Words: endothelial keratoplasty, eye bank, tissue preparation

Abbreviations: DSAEK, Descemet Stripping Automated Endothelial Keratoplasty; MK, microkeratome; ACP, anterior chamber pressure; ECD, endothelial cell density; OCT, optical coherence tomography; TT, tissue thickness; DMEK, Descemet's membrane endothelial keratoplasty; BSS, balanced salt solution

Descemet stripping automated endothelial keratoplasty (DSAEK) is a surgical procedure that involves the transplant of the donor's posterior stroma, Descemet membrane, and endothelium to patients with dysfunction of the corneal endothelium. In 2002, another partial corneal transplant procedure called Descemet's membrane endothelial keratoplasty (DMEK) was introduced that only involves the transplantation of the Descemet membrane and endothelium.¹ In published studies of experienced surgeons, DMEK was shown to have superior visual and refractive outcomes and less allograft rejection but was associated with more frequent complications, including rebubbling and iatrogenic primary graft failure.²⁻⁷ The preparation of the donor tissue for DMEK is more demanding than in DSAEK and this, in addition to the initial difficult learning curve, has led to a slow conversion to perform DMEK.⁸

In 2009, ultrathin DSAEK was introduced to achieve thinner transplant tissue.⁹⁻¹² Thinner DSAEK tissue resulted in a higher percentage of patients with 20/20 vision, faster visual recovery, and fewer complications such as endothelial cell loss, primary graft failure, and rejection rate compared to DMEK.⁶ However, other studies reported increased complications of perforation and endothelial cell damage during processing of these tissues.¹¹⁻¹³

Eye bank technicians process DSAEK tissue effectively and safely.¹⁴⁻¹⁶ However, DSAEK preparation can have varying quality as measured by graft failure, endothelial cell density (ECD) and tissue thickness (TT).¹⁴ Multiple parameters in DSAEK tissue preparation, including microkeratome (MK) head size, anterior chamber pressure (ACP), and cut pass duration can be adjusted simultaneously. Eye bank technicians follow personal algorithms

Author Affiliations: ¹ Kellogg Eye Center, University of Michigan
² SightLife

Acknowledgments: The donor patients' families for donated research tissue used in this study.

designed to help them achieve target post-processing thicknesses with combinations of MK head sizes, removal of the corneal epithelium, ACP changes, and cut pass duration in order to optimize outcomes and minimize complications or tissue loss.¹³

Eye banks utilize specular microscopy and optical coherence tomography (OCT) to obtain ECD measurements and TT, respectively, to assess tissue quality for surgical use. Currently, we do not know how variations in the processing conditions affect the quality and outcome of the processed tissues. Therefore, the purpose of our study is to determine if changes in these conditions affect ECD or TT. We also determined how TT changes over the first 24 hour post-processing period.

MATERIALS AND METHODS

Sample/Processing: Human corneas were procured according to standard local eye bank excision protocols (Eversight, Ann Arbor, Michigan; E1.220: In Situ Corneal Excision Procedure). Tissues used in this study were deemed ineligible based on donor criteria but did not have tissue parameters that would have made them ineligible. The tissues were preserved within a viewing chamber filled with Optisol GS. Prior to processing, the endothelium of each cornea was examined via slit lamp (Haag Streit; 900.7.2.2590) and specular microscopy. Endothelial cells were analyzed using specular microscopy (Konan Medical, Eye Bank Keratoanalyzer; Model#EKA-10) to document the presence of healthy cells on each cornea and ECD was recorded. Additionally, tissues were imaged with OCT (Carl Zeiss; OPMI MPU 235918) to determine changes in the tissue cut depth by altering the DSAEK preparation procedure.

All corneas underwent processing after being mounted on an artificial anterior chamber (Moria ALTK, Doylestown, PA) filled with balanced salt solution (BSS). The corneal epithelium was not removed for tissue processing. Rotary MKs with reusable heads were used to dissect the tissue. The tissue was processed using MK head sizes as follows: 13 corneas processed using a 300 μm MK head size, 13 corneas processed using a 350 μm MK head size, and 12 corneas processed using a 400 μm MK head size. Each grouping of MK head sizes included processing at specific cut pass durations that were timed via metronome. Cut pass durations of 3, 4, 5, and 6 seconds were performed three to four times for each of three MK head size groupings (300 μm , 350 μm , and 400 μm). Each of these combinations of MK head size and cut pass duration were

performed at multiple ACP levels, as measured in mmHg by digital artificial ACP gauge (Med-Logics Inc, Athens, TX). Three target ACP levels of 60 mmHg, 65mmHg, and 70mmHg were identified based on the range of pressures typical for eye bank processing of DSAEK tissues at our eye bank. Each ACP reading was allowed to stabilize prior to DSAEK processing of the tissue.

The combinations of MK head size, ACP, and cut pass duration are recorded in Table 1. After a single cut with one of these MK head size/ACP/cut pass duration combinations, the anterior cap of each tissue was adhered back to the residual stromal bed before the tissue was dismounted from the chamber, and the tissue was returned to the storage media and viewing chamber. ECD and TT were evaluated immediately after processed tissue was returned to the storage media (n=38 of 38 corneas), 30 minutes after processing (n=29 of 38 corneas), and 24 hours after processing (n=38 of 38 corneas).

Statistical Analysis: Multivariable linear regression was performed to determine an association between MK head size, ACP, and cut pass duration on ECD and tissue cut depth differences. ECD was measured as the difference between immediate post-processing ECD and pre-processing ECD. Change in tissue cut depth was measured as the difference between the 24 hour post-processing OCT measurement and pre-processing OCT measurement. Paired t-tests were also used to determine differences in TT measurements over time by OCT (immediately, 30 minutes and 24 hours after processing) and differences in ECD pre-processing and immediately post-processing.

All statistical analysis was performed using SAS 9.4 (SAS Institute, Cary NC). Our study was powered at 80%. A sample size of 33 was required to detect a 200 cells/mm² difference in ECD. A sample size of 22 was required to detect a 25 μm difference in OCT. A p-value <0.05 was determined to be statistically significant.

RESULTS

Table 1 shows the number of tissues in each category of MK head size, ACP, and cut pass duration (n=38). For target ACP levels of 60 mmHg, actual ACP ranged from 59.3 to 60.5 mmHg, with an average ACP of 59.9 mmHg; for the 65 mmHg target ACP level, actual ACP ranged from 64.6 to 65.6 mmHg, with an average ACP of 65.2 mmHg; for the 70 mmHg target ACP level, actual ACP ranged from 69.1 to 70.1 mmHg, with an average ACP of 69.5 mmHg.

Table 1: Frequency (%) of tissues in each category of microkeratome (MK) head size, anterior chamber pressure (ACP), and cut pass duration (total n=38).

Variable		Frequency (%)
MK head size (µm)	300	13 (34.21)
	350	13 (34.21)
	400	12 (31.59)
ACP (mmHg)	60	14 (36.84)
	65	12 (31.58)
	70	12 (31.58)
Cut pass duration (sec)	3	9 (23.68)
	4	11 (28.95)
	5	9 (23.68)
	6	9 (23.68)

MK, microkeratome; ACP, anterior chamber pressure

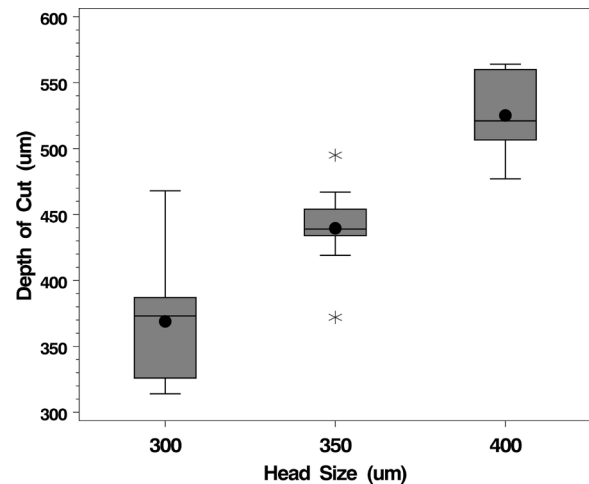


Figure 1A shows the relationship of MK (microkeratome) head size and depth of cut.

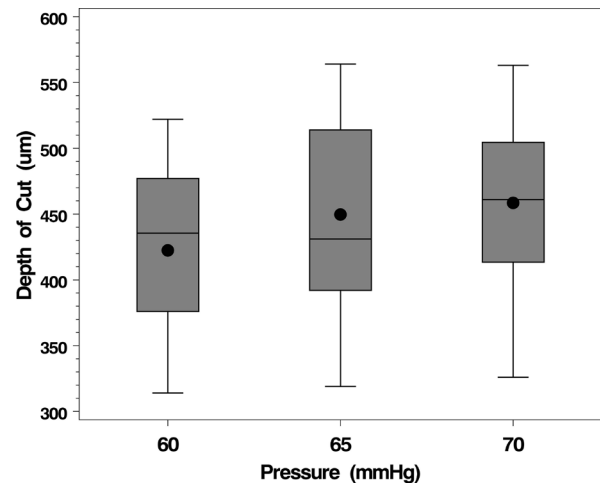


Figure 1B shows the relationship of pressure and depth of cut. Boxplots display the interquartile range (IQR), including the lower quartile/25th percentile (bottom of the box) and the upper quartile/75th percentile (top of the box), the median/50th percentile (line within the box), the mean (dot within the box), the lower fence/whisker (smallest observation within 1.5*IQR), the upper fence/whisker (largest observation within 1.5*IQR), and outliers (stars; observations located outside 1.5*IQR).

ECD before and after processing (n=38)

Change in ECD was not associated with MK head size, ACP, or cut pass duration (all p>0.05). The pre-processing ECD was 2310.24 ± 411.46 cells/mm² compared to 2327.24 ± 521.09 cells/mm² for immediate post-processing ECD (difference of 17 ± 395.4 cells/ mm²) (p=0.79).

Factors associated with TT (n=38)

In multivariable analysis, for every 50 µm increase in MK head size, the change in tissue cut depth increased by 77.32 ± 6.71 µm (p < 0.0001) (Figure 1A) For every 5 mmHg increase in ACP, the tissue cut depth increased 15.19 ± 6.59 µm (p=0.03). (Figure 1B) Cut pass duration was not significantly associated with changes in tissue cut depth (p=0.19).

Tissue Thickness Changes Over 24 Hours (n=29)

Table 2 shows mean tissue cut depth measurements pre-processing, immediate post-processing, 30 minutes post-processing, and 24 hours post-processing. There was

Table 2. Mean OCT measurements (n=29)

OCT	Mean (SD)	Difference from 24 hour post-processing	Min-Max
Pre-processing	580.00 (69.38)	443.86 (77.95)	458-723
Immediate ^a	156.86 (50.93)	20.72 (25.58)	47-271
30 minute ^a	139.28 (46.88)	3.14 (23.07)	50-258
24 hour ^a	136.14 (39.38)	-	62-200

^a post processing times
OCT, optical coherence tomography; SD, standard deviation; min, minimum; max, maximum

a mean difference of $20.72 \pm 25.58 \mu\text{m}$ between immediate post-processing and 24 hour post-processing tissue cut depth by OCT ($p < 0.001$, $n = 29$). There was a $17.59 \pm 19.14 \mu\text{m}$ mean difference between immediate post-processing and 30 minute post-processing tissue cut depth by OCT ($p < 0.001$, $n = 29$). However, there was a non-significant difference between 30 minute post-processing and 24 hour post-processing tissue cut depth by OCT ($p = 0.47$, $n = 29$).

DISCUSSION

MK head size and ACP play a role in changes in the amount of tissue removed during DSAEK tissue processing while cut pass duration does not. Currently, MK head size is selected by the technician based on the target post-processing TT and the technician's personal algorithm. MK head sizes greater than $350 \mu\text{m}$ can be associated with an increased risk of tissue perforation.¹⁷ Larger MK head sizes have been associated with greater variation in final thickness of the graft.^{12, 17} In this study, our multivariable model showed that for every 50 micron increase in MK head size, 77.32 more microns greater depth was cut. In addition, a 5 mmHg increase in ACP, 15.19 more microns greater depth was cut. MK head size, ACP, and cut pass duration were not associated with changes in ECD.

Researchers propose that donor tissues swell with corneal hydration with balanced salt solution. DSAEK grafts reach stabilization of thickness around two hours after the MK cut but the changes in graft shape were found to be insignificant.¹⁸ Our results also showed that immediate post-processing tissue cut depth was significantly different from 30 minutes and 24 hours post-processing tissue cut depth by approximately 20 microns. For eye bank preparation, this suggests that TT measurements taken at later time points are more representative of the DSAEK grafts at the time of surgery. Corneal hydration could explain the difference between the TT measured immediately post-processing from TT measured at 30 minutes and 24 hours.

Our study has limitations, including a small sample size. There were not many tissues in each category of MK head size, ACP, and cut pass duration, which makes it difficult to generalize our results to all combinations of these factors. Changing multiple parameters in a small number of tissues impacts the statistical power of the study. Future work should explore whether processing with BSS or storage solution in an artificial AC makes a difference in the effect of cut pass duration.

Variations in MK head size and ACP result in clinically significant changes in tissue cut depth during DSAEK tissue processing. MK head size, ACP, and cut pass duration do

not affect post-processing tissue ECD. Current protocols allowing for variations of these conditions do not appear to affect tissue quality in terms of TT or ECD.

REFERENCES

- Melles GR, Lander F, Rietveld FJ. Transplantation of Descemet's membrane carrying viable endothelium through a small scleral incision. *Cornea* 2002; 21: 415-418.
- Guerra FP, Anshu A, Price MO et al. Descemet's Membrane Endothelial Keratoplasty: prospective study of 1-year visual outcomes, graft survival, and endothelial cell loss. *Ophthalmology* 2011; 118: 2368-2373.
- Ham L, Balachandran C, Verschoor CA et al. Visual Rehabilitation Rate After Isolated Descemet Membrane Transplantation. *Arch of Ophthalmol* 2009; 127: 252-255.
- Tourtas T, Laaser K, Bachmann BO et al. Descemet Membrane Endothelial Keratoplasty Versus Descemet Stripping Automated Endothelial Keratoplasty. *Am J of Ophthalmol* 2012; 153: 1082-1090.
- Hamzaoglu EC, Straiko MD, Mayko ZM et al. The First 100 Eyes of Standardized Descemet Stripping Automated Endothelial Keratoplasty versus Standardized Descemet Membrane Endothelial Keratoplasty. *Ophthalmology* 2015; 122: 2193-2199.
- Busin M, Madi S, Santorum P et al. Ultrathin Descemet's Stripping Automated Endothelial Keratoplasty with the Microkeratome Double-Pass Technique. *Ophthalmology* 2013; 120: 1186-1194.
- Droutsas K, Lazaridis A, Papaconstantinou et al. Visual Outcomes After Descemet Membrane Endothelial Keratoplasty Versus Descemet Stripping Automated Endothelial Keratoplasty—Comparison of Specific Matched Pairs. *Cornea* 2016; 35: 765-771.
- Boynton GE, Woodward MA. Evolving Techniques in Corneal Transplantation. *Curr Surg Rep* 2015; 3: 2.
- Busin M, Albé E. Does thickness matter: ultrathin Descemet stripping automated endothelial keratoplasty. *Curr Opin in Ophthalmol* 2014; 25: 312-318.
- Busin M, Patel AK, Scoria V et al. Microkeratome-assisted preparation of ultrathin grafts for descemet stripping automated endothelial keratoplasty. *Invest. Ophthalmol. Vis. Sci.* 2012; 53: 521-524.
- Waite A, Davidson R, Taravella MJ. Descemet-stripping automated endothelial keratoplasty donor tissue preparation using the double-pass microkeratome technique. *J Cataract Refract Surg* 2013; 39: 446-450.
- Sikder S, Nordgren RN, Neravetla SR et al. Ultra-thin donor tissue preparation for endothelial keratoplasty with a double-pass microkeratome. *Am J Ophthalmol.* 2011; 152: 202-208.
- Woodward MA, Titus M, Mavin K et al. Corneal donor tissue preparation for endothelial keratoplasty. *J Vis Exp* 2012; 64: e3847. doi: 10.3791/3847.
- Boynton GE, Woodward MA. Eye-bank preparation of endothelial tissue. *Curr Opin in Ophthalmol* 2014; 25: 319-324.
- Nelson BA, Ritenour RJ. Tissue quality of eye-bank-prepared pre-cut corneas for Descemet's stripping automated endothelial keratoplasty. *Can J Ophthalmol* 2014; 49: 92-95.
- Kanavi MR, Javadi MA, Javadi F et al. Preparation of pre-cut corneas from fresh donated whole globes for Descemet's stripping automated keratoplasty: 3-year results at the Central Eye Bank of Iran. *Cell Tissue Bank* 2013; 15: 369-372.
- Price MO, Price FW Jr. Descemet's stripping with endothelial keratoplasty: comparative outcomes with microkeratome-dissected and manually dissected donor tissue. *Ophthalmology* 2006; 113: 1936-1942.
- Tang M, Stoeger C, Galloway J et al. Evaluating DSAEK graft deturgescence in preservation medium after microkeratome cut with optical coherence tomography. *Cornea* 2013; 32: 847-850.