CASE  
REPORT

# Specular Microscopic Imaging Results May Be Deceiving, as Demonstrated by Vital Dye Staining

Hisham A. Saad, MD; Christopher Stoeger, CEBT

## ABSTRACT

**PURPOSE:** To describe a case where specular microscopy data relayed misleading information regarding the quality of a cornea processed in an eye bank for endothelial keratoplasty.

**METHODS:** A cornea was prepared by microkeratome for endothelial keratoplasty and was evaluated with routine slit lamp and specular microscopy. In addition, the tissue was stained with trypan blue and alizarin red S to demonstrate the efficacy of the preliminary evaluation with endothelial viability studies. The stained cornea was photographed, and the percent cell death was calculated using Adobe Photoshop analysis.

**RESULTS:** The preresection central endothelial cell density was 2608 cells/mm<sup>2</sup>. In comparison, the post-cut density was 2978 cells/mm<sup>2</sup>, a figure that represents a 14.19% cell gain. Viability staining with analysis showed 43.77% cell damage.

**CONCLUSIONS:** Reliance on specular microscopy for determination of endothelial viability can lead to misleading conclusions, as demonstrated in this case study.

**KEYWORDS:** endothelial keratoplasty, microkeratome, vital stain, slit lamp, specular microscopy

Selective endothelial keratoplasty (EK) has attracted the attention of cornea surgeons over the last decade as an alternative solution to the standard penetrating keratoplasty (PK) for patients with advanced Fuchs dystrophy and bullous keratopathy.<sup>1,2</sup>

The first technique introduced by Melles as posterior lamellar keratoplasty consisted of manually dissecting the recipient and donor corneas at 80% to 90% stromal depth, excising the posterior recipient stroma and endothelium with a trephine and/or scissors, and inserting the donor button. A second technique was also described by Melles and involved stripping the Descemet membrane with the underlying diseased

endothelium from the recipient cornea, followed by insertion of a posterior donor tissue.<sup>3-5</sup>

Automated donor tissue preparation has popularized EK, and in turn, more eye banks have begun to offer pre-cut corneal tissues that are ready for trephination by the surgeon. Typically, the epithelial cap is replaced on the stromal bed after resection, and then the pre-cut tissue is stored in preservation media until used in surgery. The main advantage of using pre-cut tissue is that the surgeon no longer has to learn the delicate skills of deep stromal dissection and thus avoids possible complications related to cutting the tissue improperly. Subsequently, the surgery has become faster and easier.<sup>6,7</sup>

**Author Affiliations:** Ophthalmology Department, Tanta Faculty of Medicine, Tanta, Egypt (Dr Saad); and Lions VisionGift, Portland, Oregon (Mr Stoeger).

**Corresponding Author:** Hisham Saad, MD, Tanta Faculty of Medicine, Cornea and Refractive Surgery Unit, Magrabi Eye Hospital, 107 El Guish St, Floor 2, Tanta, El Gharbeya, Egypt (hishamhasby@yahoo.com).

**Author Disclosure:** One of the authors (Mr. Stoeger) reports that Konan has in the past supported specular research at Lions VisionGift, Portland, Oregon, with a small grant in the form of a discount on its equipment.

The essential goal of a successful EK is providing the recipient with healthy donor endothelium to resolve the corneal edema and leaving an optically pure cornea.<sup>8-10</sup> Specular microscopy has been used in many studies to examine the corneal endothelial layer *in vitro* on the donor cornea before transplantation and *in vivo* after transplantation.<sup>6-14</sup> In addition to estimating the central endothelial cell density, specular microscopy can also be used to evaluate variations in cell size (polymegathism) and cell shape (pleomorphism).<sup>15</sup> However, central endothelial cell density calculation using specular microscopy does not take into consideration those cells with degenerative changes and may count them as healthy viable cells, although they may be dead or at least have degenerative changes. In addition, specular microscopy only samples a very small area of the cornea and can completely miss any paracentral or peripheral cell loss, even when the loss is extensive.

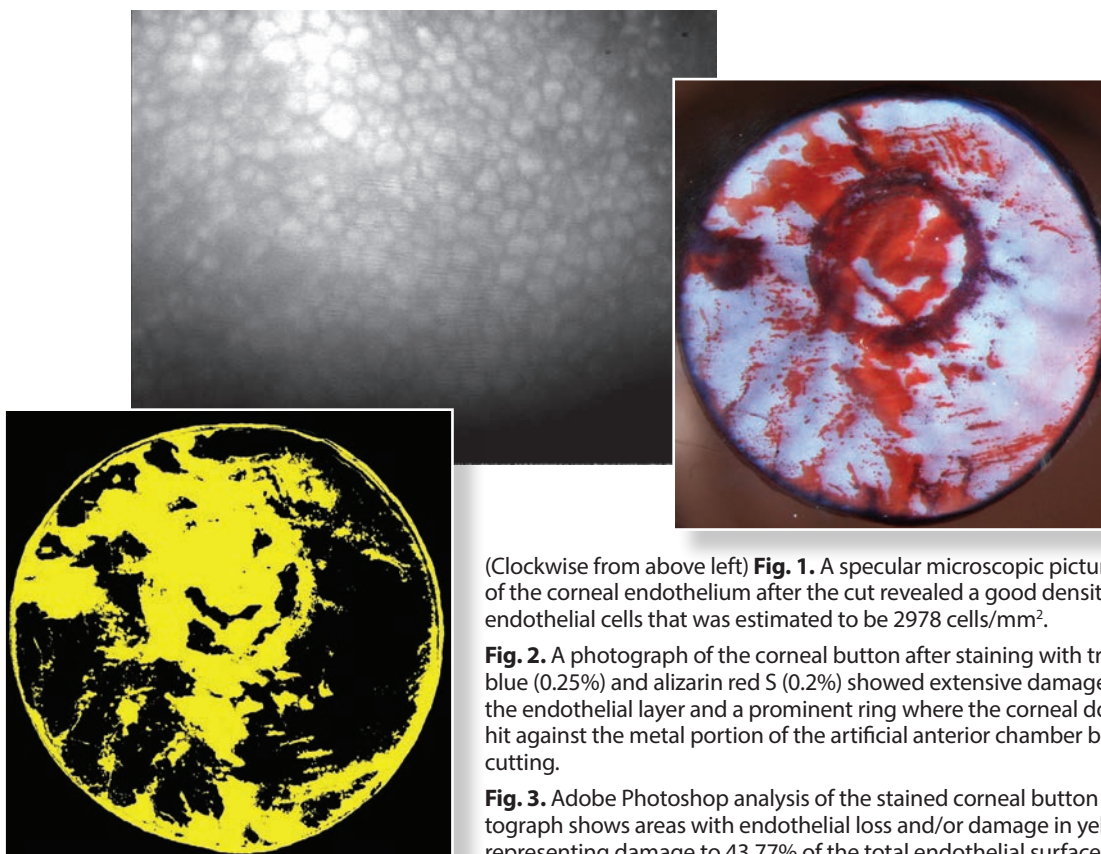
On the other hand, the use of vital dye staining of the corneal endothelium with trypan blue and alizarin red S has proven to be effective in determining areas of endothelial cell loss and/or damage. Trypan blue penetrates cells with damaged plasma membranes and stains their nuclei blue, while alizarin red S stains in red the intercellular spaces and Descemet membrane in areas with detached or necrosed endothelial cells.<sup>15-19</sup> These dyes are particularly useful for elucidating cellular damage; however, only trypan blue is appropriate for clinical use as alizarin red can be toxic to cells. This dual stain is an ideal method to confirm damage in corneas not released for transplantation.

## **METHODS**

A corneoscleral button was taken from a 50-year-old male donor. The tissue had a death-to-preservation time of 10.67 hours, was stored in Optisol GS preservative media (Bausch + Lomb, Emeryville, CA), and was refrigerated at a temperature of 2°C to 8°C. After 48 hours, the tissue was taken out of the refrigerator inside the containing chamber, and left at room temperature for an hour to warm up. Then, the tissue was examined by specular microscopy (Model EB 3000, HAI Labs, Lexington, MA) where the central endothelial cell density was found to be 2608 cells/mm<sup>2</sup>. Using our eye bank's standard cell counting protocol, cells were counted from the central cornea using the

variable frame method and counting a minimum of 100 cells. A single large field was counted. The tissue was taken immediately out of the containing chamber and mounted on an Optisol GS bubble in the Moria artificial anterior chamber (Moria, Doylestown, PA) which was then pressurized to approximately 90 mm Hg. Ultrasonic pachymetry (Pachette 2, DGH Technology Inc, Exton, PA) was performed, showing a central corneal thickness of 490 μm. During installation of the turbine microkeratome to cut the tissue, the pressure inside the artificial anterior chamber was lost by mistake, resulting in collapse of the corneal dome that hit against the metal of the artificial chamber. The pressure was restored, and the tissue was cut using the 300 micron CB head of Moria microkeratome system. The achieved thickness of the bed was 180 μm. The free cap was repositioned and the artificial chamber was dismounted. The tissue was replaced in Optisol GS and again examined by specular microscopy with the previously described protocol. The same field of cells was likely not counted; however, the sample was from the central cornea that is in the same area as the preresection sample. Amazingly, the central endothelial cell density was 2978 cells/mm<sup>2</sup> (Fig. 1). Slit lamp examination noted damage, and the tissue was rejected for transplantation. The decision was based on the slit lamp findings of an experienced eye bank technician and deviation from protocol during the precutting procedure.

The tissue was stained and analyzed according to previously described reports.<sup>17-19</sup> The technique is described here in brief. The tissue was carefully taken out of the Optisol GS medium and placed on a trephine block endothelial side up. A Barron donor punch (8.0 mm) (Katena, Denville, NJ) was used to cut the tissue. Trypan blue (0.25% solution) (MP Biomedicals, LLC, Solon, OH) was added drop-wise to cover the endothelium. After 120 seconds, the stain was poured off, and the corneal graft was briefly rinsed twice in Balanced Salt Solution (BSS; Alcon, Fort Worth, TX), drained to remove excess BSS, and then placed on a glass slide, with the endothelial surface facing up. The endothelial layer was then covered with alizarin red S (0.2% solution) (GFS Chemicals Inc., Columbus, OH) for 90 seconds, the staining reagent poured away, and the layer was again rinsed twice in BSS. The tissue was then placed in a clear glass vial containing BSS and photographed on the slit lamp.



(Clockwise from above left) **Fig. 1.** A specular microscopic picture of the corneal endothelium after the cut revealed a good density of endothelial cells that was estimated to be 2978 cells/mm<sup>2</sup>.

**Fig. 2.** A photograph of the corneal button after staining with trypan blue (0.25%) and alizarin red S (0.2%) showed extensive damage of the endothelial layer and a prominent ring where the corneal dome hit against the metal portion of the artificial anterior chamber before cutting.

**Fig. 3.** Adobe Photoshop analysis of the stained corneal button photograph shows areas with endothelial loss and/or damage in yellow, representing damage to 43.77% of the total endothelial surface.

## RESULTS

The preresection central endothelial cell density was 2608 cells/mm<sup>2</sup>, compared with the post-cut density of 2978 cells/mm<sup>2</sup> (Fig. 1). This represents a 14.19% cell gain. Staining the endothelial layer with trypan blue and Alizarin red S demonstrated extensive damage and/or loss of endothelial cells over the entire surface. Examination noted a remarkable ring that represented where the corneal dome had hit against the metal of the artificial anterior chamber (Fig. 2). Using Adobe Photoshop software (Adobe Systems, Inc., San Jose, CA) to analyze the picture, calculations revealed 43.77% endothelial surface damage (Fig. 3).

## DISCUSSION

Apart from the odd finding of a post-cut endothelial cell gain (possibly attributable to specular microscopic sampling variation), it is critical to emphasize the fact that eye bank specular microscopes typically sample only a very small central area of the whole endothelial

surface. This characteristic is due to limitations in the mechanism designed to hold the tissue in place for viewing. Due to this limitation, specular microscopy can completely miss any paracentral or peripheral endothelial damage, even when the damage is extensive. Moreover, specular microscopy can allow misrecognition of those cells with degenerative changes and permit mischaracterization of them as healthy, viable cells. Such cells may be dead, or at least have degenerative changes not apparent as long as their cell membranes are intact.

Our study confirms the importance of examining the endothelial surface on the slit lamp after cutting and not depending on the specular microscopic impression alone. Using vital dye staining and Adobe Photoshop software enabled us to examine the whole endothelial surface both quantitatively and qualitatively. We hope that in the future we will have a tool that enables us to examine the whole endothelial surface both quantitatively and qualitatively in order to ensure adequate tissue quality post-processing. To that end, further research is warranted in order to deploy such a methodology for widespread use.

## REFERENCES

1. Claesson M, Armitage WJ, Fagerholm P, et al. Visual outcome in corneal grafts: a preliminary analysis of the Swedish Corneal Transplant Register. *Br J Ophthalmol.* 2002;86(2):174-80. doi:10.1136/bjo.86.2.174.
2. Pineros OE, Cohen EJ, Rapuano CJ, et al. Triple vs nonsimultaneous procedures in Fuchs' dystrophy and cataract. *Arch Ophthalmol.* 1996;114(5):525-528. doi:10.1001/archophth.1996.01100130517002.
3. Melles GR, Eggink FA, Lander F, et al. A surgical technique for posterior lamellar keratoplasty. *Cornea.* 1998;17(6):618-626. PMID: 9820943.
4. Melles GR, Lander F, Nieuwendaal C. Sutureless, posterior lamellar keratoplasty: a case report of a modified technique. *Cornea.* 2002;21(3):325-327. PMID: 11917186.
5. Melles GR, Wijdh RH, Nieuwendaal, CP. A technique to excise the descemet membrane from a recipient cornea (descemetorhexis). *Cornea.* 2004; 23(3):286-288. PMID: 15084862.
6. Gorovoy MS. Descemet-stripping automated endothelial keratoplasty. *Cornea.* 2006;25(8):886-889. doi:10.1097/01.icc.0000214224.90743.01.
7. Price MO, Price FW. Descemet's stripping with endothelial keratoplasty: Comparative outcomes with microkeratome-dissected and manually dissected donor tissue. *Ophthalmology.* 2006;113(11):1936-1942. doi:10.1016/j.ophtha.2006.05.034.
8. Terry MA. Endothelial Replacement Surgery. In: Krachmer JH, Mannis MJ, Holland EJ, eds. *Cornea: Surgery of the Cornea and Conjunctiva.* 2<sup>nd</sup> ed, St. Louis, MO: Elsevier Mosby; 2005:1707-1718. ISBN 0323023150.
9. Price FW, Price MO. Descemet's stripping with endothelial keratoplasty in 200 eyes: Early challenges and technique to enhance donor adherence. *J Cataract Refract Surg.* 2006;32(3):411-418. doi:10.1016/j.jcrs.2005.12.078.
10. Terry MA, Ousley PJ. Deep lamellar endothelial keratoplasty (DLEK): Visual acuity, astigmatism, and endothelial survival in a large prospective series. *Ophthalmology.* 2005;112(9):1541-1549. doi:10.1016/j.ophtha.2005.03.026.
11. Ousley PJ, Terry, MA. Stability of vision, topography, and endothelial cell density from 1 year to 2 years after deep lamellar endothelial keratoplasty (DLEK) surgery. *Ophthalmology.* 2005;112(1):50-57. doi:org/10.1016/j.ophtha.2004.07.028.
12. Van Dooren B, Mulder PG, Nieuwendaal CP, et al. Endothelial cell density after posterior lamellar keratoplasty (Melles techniques): 3 years follow-up. *Am J Ophthalmol.* 2004;138(2):211-217. doi:10.1016/j.ajo.2004.02.016.
13. Fogla R, Padmanabhan P. Initial results of small incision deep lamellar endothelial keratoplasty (DLEK). *Am J Ophthalmol.* 2006; 141(12): 346-351. doi:10.1016/j.ajo.2005.10.010.
14. Wilson SE, Bourne WM. Corneal preservation for penetrating keratoplasty. In: Kaufman HE, Barron BA, McDonald MB, eds. *The Cornea.* 2nd ed. Boston, MA: Butterworth-Heinemann; 1998:781-803.
15. Spense DJ, Peyman GA. A new technique for the vital staining of the corneal endothelium. *Invest Ophthalmol.* 1976; 15(12): 1000-1002.
16. Taylor MJ, Hunt CJ. Dual staining of corneal endothelium with trypan blue and alizarin red S: importance of pH for the dye-lake reaction. *Br J Ophthalmol.* 1981;65(12):815-819. doi.org:10.1136/bjo.65.12.815.
17. Saad HA, Terry MA, Shamie N, et al. An easy and inexpensive method for quantitative analysis of endothelial damage by using vital dye staining and Adobe Photoshop software. *Cornea.* 2008;27(7):818-824. doi:10.1097/ICO.0b013e3181705ca2.
18. Terry MA, Saad HA, Shamie N, et al. Endothelial keratoplasty: the influence of insertion techniques and incision size on donor endothelial survival. *Cornea.* 2009;28(1):24-31. doi:10.1097/ICO.0b013e318182a4d3.
19. Terry MA, Saad HA, Shamie N, et al. Peripheral endothelial cell damage after trephination of donor tissue. *Cornea.* 2009;28(10):1149-1152. doi:10.1097/ICO.0b013e3181a87a28.