

RESEARCH

A Prospective, Randomized Trial of DSAEK Outcomes Comparing Different Donor Preparation Devices

W. Barry Lee, MD; Bryan E. Lusk, MD; Michael J. Lynn, MS

ABSTRACT

PURPOSE: To determine whether Descemet stripping automated endothelial keratoplasty (DSAEK) outcomes differ between precut or surgeon-cut donor tissue and the Horizon or Moria systems.

DESIGN: This study was a randomized, prospective, double-masked clinical trial.

METHODS: Sixty-three consecutive DSAEK surgeries underwent tissue randomization. Thirty-three eyes underwent DSAEK using precut donor tissue prepared with the Horizon system (Group 1) and 30 eyes underwent DSAEK using tissue prepared by the surgeon with the Moria system (Group 2). Main outcome measures included visual acuity, mean endothelial cell loss, graft clarity, and complication rates.

RESULTS: The mean patient age was 70 years \pm 10 years (range, 55–87), with 52 eyes (83%) having Fuchs endothelial corneal dystrophy and 11 eyes (17%) with pseudophakic bullous keratopathy. Mean preoperative best spectacle-corrected visual acuity (BSCVA) was 20/96 (0.68) in Group 1 and 20/130 (0.81) in Group 2 ($P = 0.19$), and the mean postoperative BSCVA was 20/39 (0.29) in Group 1 and 20/47 (0.37) in Group 2 ($P = 0.25$). Mean endothelial cell loss at 12 months was 30.9% in Group 1 and 28.2% in Group 2 ($P = 0.28$). Mean induced astigmatism at 6 months was $-0.01D$ in Group 1 and $0.17D$ in Group 2 ($P = 0.59$). Group 1 had 3 (9.1%) tissue dislocations and Group 2 had 2 (6.5%) tissue dislocations ($P = 0.1$). Group 1 had 1 (3.0%) primary graft failure (PGF) and Group 2 had none ($P = 0.1$). Endothelial graft rejection and pupil block glaucoma were not observed.

CONCLUSIONS: No statistical difference was observed in DSAEK outcomes regardless of whether the tissue was precut or surgeon-cut or whether prepared by the Horizon or Moria devices.

KEYWORDS: endothelial keratoplasty, DSAEK, microkeratome, precut tissue

Descemet stripping automated endothelial keratoplasty (DSAEK) remains the most commonly utilized form of endothelial keratoplasty among corneal surgeons for the surgical treatment of endothelial diseases of the cornea.¹⁻⁹ Widespread and rapid adoption of endothelial keratoplasty (EK) by corneal surgeons in the United States is corroborated by statistics released by the Eye Bank Association of America (EBAA) in 2011, in which 1,429 EK surgeries were performed in 2005 compared with 23,287 EK surgeries distributed among eye banks within the EBAA in 2011. The popularity of DSAEK is attributed to its multiple advantages over penetrating keratoplasty (PK),

including avoidance of an “open sky” technique, more rapid vision recovery, and avoidance of long-term sutures needed for adherence of the donor cornea, resulting in improved tectonic stability and reduced postoperative astigmatism.⁹

Historically, donor tissue preparation for DSAEK, whether precut or surgeon-cut, has been performed with the Moria ALTK System (Moria Surgical, Antony, France); however, the newer Horizon DSAEK system (Horizon, Cleveland, Ohio) is now available for donor tissue preparation. This system provides unique advantages to eye banks that do not have sterilization capability, as it is completely disposable and avoids the need for expensive sterilization equipment.

Author Affiliations: Cornea Service, Piedmont Hospital / Eye Consultants of Atlanta (Dr Lee and Dr Lusk); Georgia Eye Bank, Atlanta (Dr. Lee); and Emory University, Department of Biostatistics, Atlanta (Mr. Lynn).

Corresponding Author: W. Barry Lee, MD, Piedmont Hospital / Eye Consultants of Atlanta, 3225 Cumberland Boulevard, Suite 900 Atlanta, GA 30339 (Lee0003@aol.com).

The authors state that they have no conflicts of interest to disclose.

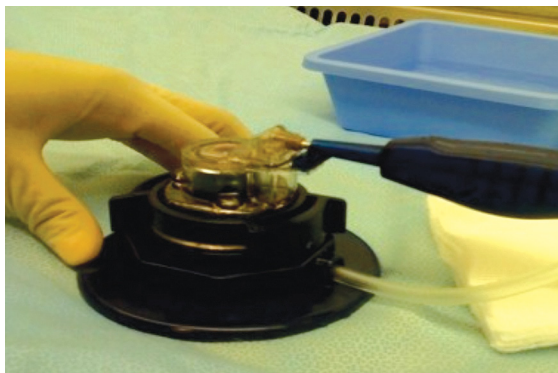

Fig. 1A. The Horizon DSAEK system.

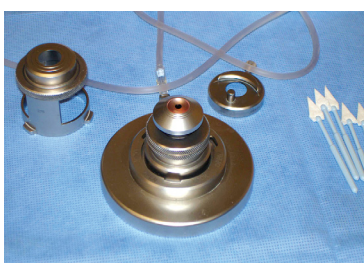

Fig. 1B. The Moria artificial anterior chamber system.

Precut tissue from eye banks presents several inherent advantages, including increased surgeon efficiency, decreased surgical center expense (microkeratome blades, nitrogen gas, and an artificial anterior chamber and lamellar equipment), and avoidance of intraoperative donor tissue perforation during preparation.^{10,11}

While precut tissue possesses several advantages, it also raises several procedure-related questions, including outcomes of precut DSAEK tissue preparation performed by an eye bank technician compared to a corneal surgeon, potential altered endothelial preservation of donor tissue, and altered postoperative outcomes from additional tissue manipulation and corneal storage media tissue effects. Several studies from 1 eye bank have demonstrated the safety and excellent outcomes from precut DSAEK tissue, although more studies are needed to answer these important questions.¹²⁻¹⁴ Given these considerations, we investigated whether a difference in DSAEK outcomes existed between precut tissue made from the disposable Horizon DSAEK system (Fig. 1A) and surgeon-cut tissue prepared by the Moria ALTK system (Fig. 1B) at the time of surgery through a randomized, prospective, controlled trial.

To our knowledge, this study represents the first randomized, prospective trial evaluating 2 different artificial anterior chamber devices and the second trial to date comparing precut and surgeon-cut donor tissue preparations. All precut tissue was prepared on the day of surgery to prevent donor changes from overnight tissue storage. This study was undertaken to determine whether a difference could be observed between precut and surgeon-cut tissue and whether the use of different artificial anterior chamber devices would result in different outcomes.

METHODS

Protocol

Institutional review board approval was obtained for a prospective, randomized trial with the development of a Health Information Portability and Accountability Act-compliant clinical protocol and surgical consent form for DSAEK. Sixty-three patients with endothelial dysfunction due to either Fuchs endothelial corneal dystrophy or pseudophakic bullous keratopathy were recruited. These participants were scheduled to undergo routine DSAEK in this randomized, prospective, double-masked study. Subjects were treated with DSAEK at a single tertiary referral center (WBL) from January 2009 to August 2009. Thirty-three eyes underwent DSAEK using precut donor tissue prepared with the Horizon system (Group 1) and 30 eyes underwent DSAEK using tissue prepared with the Moria system by the surgeon (Group 2). All cases were prospectively analyzed with final data obtained at a 12-month postoperative visit for the outcome measures of best spectacle-corrected visual acuity (BSCVA), postoperative complications such as graft dislocation and induced topographic astigmatism, and mean donor endothelial cell loss compared with preoperative measurements.

Randomization

An independent eye bank coordinator randomly assigned the donor corneas to a patient once the study design was outlined and approved. Donor corneas for Group 1 were prepared by the eye bank technician as outlined in the donor preparation section. Corneas were distributed to a designated independent surgical coordinator at the surgery center, and a logbook detailing which patients were in Group 1 and Group 2 was kept throughout the study period until all patients completed a 12-month follow-up, at which time the results were released to the surgeon and statistician. The study participants were masked regarding their tissue assignment. In addition, the physician and ophthalmic technicians who conducted postoperative assessments were masked regarding the tissue assignment.

Donor tissue preparation

An experienced eye bank technician (>100 cuts to surgeons for DSAEK prior to study) prepared all pre-cut donor cornea tissue on the Horizon DSAEK system on the morning of surgery for Group 1. After the donor cornea was centered in the artificial anterior chamber, the air pressure was raised to a minimum of 23.5 mm Hg. After adequate air pressure was achieved

within the artificial chamber, 4 radial gentian violet marks were made on the cornea after the epithelium was removed for future replacement of the anterior corneal donor cap. The epithelium was removed from the donor cornea and the central corneal thickness (CCT) was measured by ultrasonic pachymetry. The disposable system nomogram provided by the Horizon system was implemented to make the appropriate sized cut in the donor tissue based on the CCT, using either a 250-, 300-, or 400-micron cutting blade with a microkeratome head diameter of 10 mm. The donor cap was replaced using the previously created marks. The pre-cut donor corneas were shipped in Optisol-GS (Bausch + Lomb, Rochester, New York). In all cases, the anterior caps remained in place during shipment. All pre-cut corneas were transplanted after preparation and delivery by the eye bank.

Preparation of surgeon-cut tissue (Group 2) involved mounting the donor corneoscleral button on an artificial anterior chamber designed for use with a microkeratome (Moria) after removal from the storage medium. The anterior chamber was filled with balanced salt solution. The epithelium was removed from the donor cornea and CCT was measured by ultrasonic pachymetry. If the thickness was greater than 575 microns, a 350-micron microkeratome depth plate was selected. If the donor thickness was less than 575 microns, a 300-micron depth plate was selected. After the donor graft was dissected, the anterior cap was replaced on the stromal bed and the center was marked with gentian violet.

The eye bank technician randomly assigned corneas for either pre-cut or surgeon-cut groups. Precutting was performed by the Georgia Eye Bank using a Horizon DSAEK system, whereas surgeon cutting was performed using the Moria system. The surgical schedule, or order of DSAEK patients, was determined based on need and severity of patients' disease. An operating room technician kept a log of which patients received pre-cut versus surgeon-cut tissue. This was not referenced by the principal investigators until the end of the study, at which point the study log was unmasked.

Surgical procedure

The DSAEK surgical technique used for all cases involved removal of the donor tissue from the storage vial. The donor cap was removed and multiple gentian violet marks were placed around the flap edge on the non-cut edge of the tissue, taking care to avoid adding ink into the pre-cut stromal interface to avoid potential donor endothelial toxicity. The tissue was centered on the Hanna cutting block, and an 8.5-mm donor cut was created for all cases. The tissue was then placed

in an anti-desiccation chamber with a few drops of balanced salt solution prior to transplantation. Healon (Abbott Medical Optics, Santa Ana, California) was used for anterior chamber maintenance and a near-clear temporal incision was enlarged to 5 mm in all cases. A 7-mm zone of recipient endothelium/Descemet membrane was removed using a reverse Sinsky hook followed by peripheral scraping of the peripheral recipient stroma as described by Terry et al.⁶ Two vent incisions were placed with a 15° blade extending 1 mm in the superior and inferior paracentral corneas inside the area of stripped recipient tissue. Viscoelastic was removed from the eye and a plastic glide trimmed to 4.5 mm in width was inserted through the incision. The external portion of the glide was coated vigorously with Healon, and the posterior donor tissue lenticule was placed endothelial-side down on the viscoelastic. A 30-gauge needle on a 3-cc syringe was used to engage the anterior edge of the donor stromal tissue side and push the tissue through the 5-mm incision along the glide with instant opening in the anterior chamber (Fig. 2). The viscoelastic was rinsed away with balanced salt solution irrigation at the wound to prevent extra entry into the anterior chamber. Two to three 10-0 nylon sutures were used to close the incision, and balanced salt solution was introduced through the paracentesis to increase the anterior chamber depth. An air-fluid exchange was performed by injecting air through a cannula under the donor tissue. Some cases required air to be inserted through a 30-gauge needle to achieve complete air filling. A fluid massage over the recipient epithelium was performed with a cannula to sweep fluid from the interface, followed by expression of potential interface fluid from the vent incisions using a Sinsky hook. After 8–10 minutes of observation, subconjunctival cefazolin and Decadron (dexamethasone) were injected. The patient was placed in a supine position in the post-op recovery unit and taken to the slit lamp after approximately 60–90 minutes. At the slit lamp, gentle pressure was applied to the paracentesis site with a 27-gauge cannula to release air from the anterior chamber until the

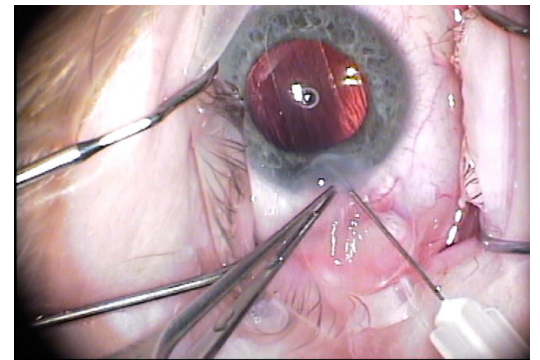


Fig. 2. A 30-gauge needle engages the anterior stromal surface of the posterior donor tissue to facilitate pushing the donor tissue through the 5-mm incision along the Healon-coated glide.

air bubble was positioned at or above the middle pupil border to prevent pupil block. Patients received a drop of 1% cyclopentolate (Cyclogyl: Alcon, Fort Worth, Texas), 0.5% gatifloxacin (Zymar: Allergan, Irvine, California), and 1% prednisolone acetate (Pred Forte: Allergan, Irvine, California) prior to taping of the lid and placement of an eye shield. Patients were discharged and instructed to lie on their backs or in a recliner for the remainder of the day until postoperative day 1.

Postoperatively, patients were prescribed 1% prednisolone acetate 6 times daily and 0.5% gatifloxacin 4 times daily for 10 days. Patients typically continued 4-times-daily topical steroid therapy after the 1–2-week postoperative visit for the first 3 months after surgery. After 3 months, the topical steroid was tapered by 1 drop every 2 months until the dose was eventually taken once daily using 1% prednisolone acetate at the study endpoint.

Outcome measures

The main outcome measures included 12-month postoperative visual acuity, dislocation rate, percentage of endothelial cell loss, and mean induced non-vector astigmatism. Visual acuity was assessed by converting the patient’s 12-month post-operative Snellen acuity (feet) to the LogMAR decimal system to facilitate statistical analysis. Induced astigmatism was evaluated by comparing pre- and postoperative corneal topography and/or manifest refractions. The preoperative endothelial cell count was determined at the eye bank using noncontact specular microscopy, which was performed after cutting of the graft for precut eyes, whereas postoperative endothelial cell count was determined by Confoscan 4 (Nidek Technologies, Padua, Italy) confocal microscopy.

Table 1. Patient Demographics for Groups 1 and 2

	Group 1: Precut Horizon Eyes	Group 2: Surgeon-cut Moria Eyes
Eyes (N)	33	30
Gender (female:male)	25:8	22:8
Diagnosis		
FECD (%)	26 (79)	26 (84)
PBK (%)	7 (21)	5 (16)
Pseudophakia (%)	16 (48)	16 (52)
Combined DSAEK, cataract removal & intraocular lens implant (%)	17 (52)	15 (48)
Age (mean)	71+/-13	69+/-11

Abbreviations: FECD, Fuchs endothelial corneal dystrophy; PBK, pseudophakic bullous keratopathy; DSAEK, Descemet stripping automated endothelial keratoplasty.

Statistical analysis

Statistical analysis of the results was performed by 2-sample t-test and Fisher exact test. Twelve-month postoperative visual acuity, percent endothelial cell loss, and mean induced astigmatism were evaluated by 2-sample t-test. Rates of dislocation and graft failure were evaluated by Fisher exact test. A P-value of 0.05 was considered statistically significant.

RESULTS

Patient demographics are reviewed in Table 1 and included a mean age of 70 ± 10 years, with a range of 55–87 years. Seventy-five percent of the patients were female and 25% were male. Fifty-two eyes (83%) had a diagnosis of Fuchs dystrophy and 11 eyes (17%) had pseudophakic bullous keratopathy. Thirty-three eyes (52%) were precut (Group 1) by the Georgia Eye Bank, whereas 30 eyes (48%) were cut by a single surgeon (Group 2). All patients completed a 12-month follow-up with no protocol deviations.

A review of all DSAEK outcomes is presented in Table 2.

Table 2. DSAEK Outcomes in Groups 1 and 2

	Horizon Group 1	Moria Group 2	P
Mean pre-operative BSCVA (Snellen: LogMAR)	20/96:0.679	20/132:0.814	0.190
Mean post-operative BSCVA (Snellen:LogMAR)	20/39:0.292	20/47:0.373	0.246
Mean induced non-vector astigmatism	-0.01D	0.17D	0.587
Preoperative endothelial cell count; mean (range)	2,905 (2,522 –3,257) cells/mm ²	2,950 (2,487 – 4,119) cells/mm ²	0.525
Post-operative endothelial cell count; mean (range)	2,014 (1,560 – 2,676) cells/mm ²	2,091 (1,366 – 2,689) cells/mm ²	0.308
Mean endothelial cell loss (%)	30.9	28.2	0.278
Complications			
Dislocations (N:%)	3:9.1	2:6.5	0.1
Graft failure (N:%)	1:3	0	0.1

Abbreviations: DSAEK, Descemet stripping automated endothelial keratoplasty; BSCVA, best spectacle-corrected visual acuity.

Visual acuity

The mean preoperative BSCVA was 20/96 (LogMAR 0.679) in Group 1 and 20/130 (LogMAR 0.814) in Group 2, with no statistical difference between the groups ($P = 0.190$). The mean postoperative BSCVA at 12 months was 20/39 (LogMAR 0.292) in Group 1 and 20/47 (LogMAR 0.373) in Group 2, with no statistical difference between the groups ($P = 0.246$). The 12-month postoperative visual acuity was 20/60 or better in 94% of cases in Group 1 and 84% of cases in Group 2.

Postoperative complications

The most common complication following DSAEK in both groups was graft dislocation. Group 1 had 3 dislocations (9.1%) and Group 2 had 2 dislocations (6.5%) ($P = 0.1$). All dislocations were successfully reattached with a rebubble procedure on the following day in a minor surgical suite. Overall, one patient (3%) from Group 1 developed a primary graft failure, and there were no graft failures in Group 2 ($P = 0.1$). Primary graft failure was defined as persistence of corneal edema 2 months from the surgical date. The rates of graft dislocation and graft failure between Groups 1 and 2 were not statistically significant.

The mean induced non-vector astigmatism at 12-months was $-0.01D$ in Group 1 and $+0.17D$ in Group 2, with no difference between the groups ($P = 0.587$). No pupil block glaucoma, interface complications, infection, or immune graft rejections occurred in either group.

Mean percent endothelial cell loss

All preoperative cell counts were obtained at the Georgia Eye Bank following donor tissue preparation. The preoperative mean endothelial cell count in Group 1 was 2,905 cells/mm² (range, 2,522–3,257 cells/mm²). The preoperative mean endothelial cell count in Group 2 was 2,950 cells/mm² (range, 2,487–4,119 cells/mm²). There was no significant difference between the preoperative mean endothelial cell counts ($P = 0.525$). The postoperative mean endothelial cell count was 2,014 cells/mm² for Group 1 (range, 1,560–2,676 cells/mm²) and 2,091 cells/mm² for Group 2 (range, 1,366–2,689 cells/mm²); the difference was not statistically significant ($P = 0.308$). The mean percent endothelial cell loss 12 months postoperatively was 30.9% in Group 1 and 28.2% in Group 2; the difference between the groups was not statistically significant ($P = 0.278$).

DISCUSSION

The results of this prospective, randomized, masked-evaluator clinical trial showed no statistically significant differences between donor preparation devices or precut versus surgeon-cut tissue. These findings are in agreement with previously published studies, which also found no difference between different preparation techniques (precut versus surgeon cut);^{7,10-14} however, our study also found no differences between artificial anterior chamber devices. Postoperative outcomes demonstrated that donor tissue prepared by an experienced eye bank technician utilizing the Horizon DSAEK system was comparable to surgeon-cut tissue with the Moria ALTK system in terms of 12-month postoperative BSCVA, amount of induced astigmatism, rate of dislocation and graft failure, and percent endothelial cell loss 12 months after surgery.

The postoperative outcomes of both groups compared favorably to a recent review of EK outcomes performed by the American Academy of Ophthalmology, which found that the most common complication of DSAEK was posterior graft dislocation, as shown in our study.⁹ In the present study, dislocation rates were 9.1% in Group 1 and 6.5% in Group 2, while the average rate of dislocation was 14% in the DSEK review article. The 12-month postoperative BSCVA, amount of induced astigmatism, rate of graft failure, and percent endothelial cell loss 12 months after surgery also compared favorably to those cited in the review. No statistically significant differences were noted between the various outcome measures between the 2 groups. Endothelial cell loss has remained an important concern with the evolution of surgical techniques and devices for DSAEK. The mean endothelial cell loss at 12 months in the present study was 30.9% in Group 1 and 28.2% in Group 2, slightly lower than the average of 37% cited in the DSEK review article.⁹

In terms of vision recovery in the current study, the postoperative visual acuity was approximately 1 line better in Group 1 (precut with the Horizon system), although this finding was not statistically significant. No statistical difference was observed in visual acuity between precut and surgeon-cut tissue or between the different donor tissue preparation devices. While our tissue was precut on the day of surgery, multiple studies show good outcomes with tissue precut on the day before surgery, and we do not feel the timing of eye bank tissue cutting makes a significant difference in terms of outcomes.⁷⁻¹⁴ It is also not feasible in many practices to have precut tissue prepared and delivered on the same day by the prospective eye bank.

Aspects of our study that lend strength to our argument are the randomized, prospective, and blinded nature of our study. Additionally, our same-day pre-cut grafts were more likely to provide a more reliable comparison between preoperative endothelial cell counts of surgeon-cut grafts, lending more legitimacy to endothelial cell loss at 12 months. The limitations of our study are that our sample size was small; thus, our statistical findings could have been attributed to low statistical power. Additionally, there was a small difference in the number of patients in each group. The use of 2 variables rather than a single variable of comparison between the 2 groups (different preparation techniques and different donor preparation devices) does add weakness to a randomized, controlled trial; however, use of the same devices was not logistically possible due to the availability of preparation devices in the eye bank and surgical center.

Regardless of these strengths and weaknesses of the study, we found acceptable outcomes with no long-term adverse problems when using pre-cut tissue from the eye bank, and we observed no adverse outcomes using the Horizon DSAEK system for preparation of the eye bank tissue. The outcomes of both groups revealed no statistically significant differences among all studied outcomes, and all outcomes compared favorably to previous publications regarding DSAEK. The DSAEK preparation device was particularly advantageous for the Georgia Eye Bank for a number of reasons. The disposable nature of the system afforded the ability to provide pre-cut tissue without the need to implement sterilization protocols or purchase sterilization equipment, and eye bank technicians found the system simpler and less technical in comparison to their experience using the Moria ALTK system. In addition, pre-cut tissue offers several advantages to surgical facilities and surgeons by avoiding the need to purchase expensive equipment, blades, or nitrogen gas to run the microkeratome, thereby increasing surgical efficiency by avoiding donor tissue preparation, and although a rare occurrence, avoidance of emergent case cancellations from potential intraoperative donor tissue perforation during the tissue preparation technique.

DSAEK outcomes were not statistically different in terms of visual acuity, complication rates, and endothelial cell loss at 12 months, despite whether pre-cut tissue or surgeon-cut tissue was used. In addition, no statistically significant differences were observed between DSAEK outcomes regardless of whether donor tissue was prepared by the Horizon DSAEK or the Moria ALTK systems.

REFERENCES

1. Price FW Jr., Price MO. Descemet stripping with endothelial keratoplasty in 200 eyes: early challenges and techniques to enhance donor adherence. *J Cat Refract Surg.* 2006;32(3):411-8.
2. Gorovoy MS. Descemet-stripping automated endothelial keratoplasty. *Cornea.* 2006;25(8):886-9.
3. Covert DJ, Koenig SB. New triple procedure: Descemet stripping and automated endothelial keratoplasty combined with phacoemulsification and intraocular lens implantation. *Ophthalmology.* 2007;114(7):1272-7.
4. Terry MA, Shamie N, Chen ES, et al. Endothelial keratoplasty: the influence of preoperative donor endothelial cell densities on dislocation, primary graft failure, and 1-year cell counts. *Cornea.* 2008;27(10):1131-7.
5. Chen ES, Terry MA, Shamie N, et al. Descemet-stripping automated endothelial keratoplasty: six month results in a prospective study of 100 eyes. *Cornea.* 2008;27(5):514-20.
6. Terry MA, Chen ES, Shamie N, et al. Endothelial cell loss after Descemet stripping endothelial keratoplasty in a large prospective series. *Ophthalmology.* 2008;115(3):488-96.
7. Terry MA. Endothelial keratoplasty: a comparison of complication rates and endothelial survival between pre-cut tissue and surgeon-cut tissue by a single DSAEK surgeon. *Trans Am Ophthalmol Soc.* 2009;107:184-93.
8. Price MO, Fairchild KM, Price DA, et al. Descemet stripping endothelial keratoplasty: 5-year graft survival and endothelial cell loss. *Ophthalmology.* 2011;118(4):725-9.
9. Lee WB, Jacobs DS, Musch DC, et al. Descemet stripping endothelial keratoplasty: safety and outcomes: a report by the American Academy of Ophthalmology. *Ophthalmology.* 2009;116(9):1818-30.
10. Price MO, Baig KM, Brubaker, et al. Randomized, prospective comparison of pre-cut vs surgeon-dissected grafts for descemet stripping automated endothelial keratoplasty. *Am J Ophthalmol.* 2008;146(1):36-41.
11. Chen ES, Terry MA, Shamie N, et al. Pre-cut tissue in Descemet stripping automated endothelial keratoplasty donor characteristics and early postoperative complications. *Ophthalmology.* 2008;115(3):497-502.
12. Kitzmann AS, Goins KM, Reed C, et al. Eye bank survey of surgeons using pre-cut donor tissue for descemet stripping automated endothelial keratoplasty. *Cornea.* 2008;27(6):634-9.
13. Jones YJ, Goins KM, Sutphin JE, et al. Comparison of the femtosecond laser (IntraLase) versus manual microkeratome (Moria ALTK) in dissection of the donor in endothelial keratoplasty: initial study in eye bank eyes. *Cornea.* 2008;27(1):88-93.

14. Rauenz MP, Goins KM, Sutphin JE, et al. Impact of eye bank lamellar tissue for endothelial keratoplasty on bacterial and fungal corneoscleral donor rim cultures after corneal transplantation. *Cornea*. 2012;31(4):376-9.